

Using an Abdominal Simulator to Assess Abdominal Diagnostic Accuracy

Cody A. Cox

Mentor: Rob Hamm PhD.

A Quick Recap

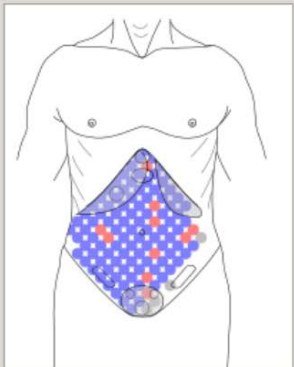
- What is the AbSim?
- What are we doing with the AbSim
- Where were we when the Summer began?
- Where are we now?
- Why is this important?

The Components of the Study

- Palpatory coverage of the abdomen

View Assessments

Exam ID		Light palpation	Deep palpation	Palpation too deep
6				
5	Appendix Region	✓	✓	
4	Colon Region	✓	✓	
3	Gallbladder Region	✓	✓	
2	Gastric/Epigastric Region	✓	✓	
1	Left Ovary Region	✓	✓	
	Right Ovary Region	✓	✓	
	Pancreatic Region	✓	✓	
	Normal Urinary Bladder	✓	✓	
	Liver Region	✓	✓	
	Splenic Region	✓	✓	
	Distended Urinary Bladder	✓	✓	



The Components of the Study

- Identification of abdominal abnormalities

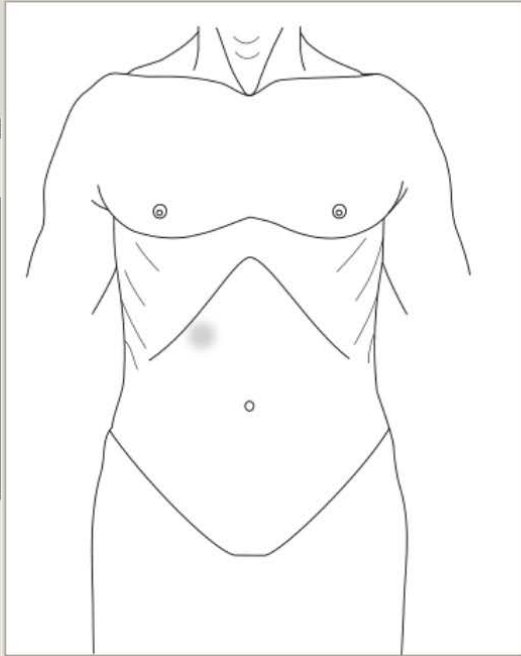
AbSim

Pressure pad is not connected! Please check the USB cable and turn off AbSim for five seconds.

Baseline Assessment	You should now understand what a normal abdomen feels like.
Milestone 1: Depth of Palpation	For this milestone, familiarize yourself with how these abnormalities feel. In the next step, you will identify them using touch and sound.
Milestone 2: Surface Area Coverage	
Comparative Assessment	
Milestone 3: Abnormality Detection	
Milestone 4: Self-Assessment with Random Ailments	
Milestone 5: Diagnosis Integration with Hx/PE	

Ailment

- ▾ Appendix Tenderness
 - With Guarding
 - With Rebound Tenderness
 - With Guarding and Rebound Tenderness
- ▾ Colon, Left Lower Tenderness
 - With Guarding
- ▾ Gallbladder Tenderness
 - With Guarding
- Gastric Tenderness
- ▾ Ovary, Left Tenderness
 - With Guarding
- ▾ Ovary, Right Tenderness



The Components of the Study

- Case integration and Diagnosis

The screenshot shows the AbSim software interface. At the top, there is a title bar with the text 'AbSim' and standard window controls. Below the title bar, a message box with a red 'X' icon reads: 'Pressure pad is not connected! Please check the USB cable and turn off AbSim for five seconds.'

The main interface is divided into three sections:

- Left Panel (Milestones):** A vertical list of milestones:
 - Baseline Assessment
 - Milestone 1: Depth of Palpation
 - Milestone 2: Surface Area Coverage
 - Comparative Assessment
 - Milestone 3: Abnormality Detection
 - Milestone 4: Self-Assessment with Random Ailments
 - Milestone 5: Diagnosis Integration with Hx/PE
- Center Panel (Text):** Contains the patient's history and physical examination findings.

HISTORY: A 67 year old female presents for an evaluation of abdominal pain. She describes the pain as gradual in onset, moderate to severe, constant, progressive worsening over time, and ongoing for approximately 8 hours prior to presentation. The location is described as right lower quadrant. She describes the following associated findings: anorexia, and feeling feverish. The patient's past medical history is unremarkable.

PHYSICAL EXAMINATION: The patient's General Appearance reveals a patient who wants to remain very still. VITAL SIGNS are remarkable for the following: temperature 38.6° C. THORAX and LUNGS are unremarkable. ABDOMINAL EXAM/INSPECTION is unremarkable. ABDOMINAL AUSCULTATION reveals: decreased bowel sounds.
- Right Panel (Diagnoses):** A vertical list of potential diagnoses:
 - Upper Gastrointestinal Etiology
 - Cholelithiasis
 - Pancreatitis
 - Cholecystitis
 - Mesenteric Infarction
 - Small Bowel Obstruction
 - Appendicitis
 - Diverticulitis
 - Acute Enteritis

The Evolution of an Abdominal Case

- Why do we need different cases?
- Selecting new cases
- The fine line between easy and hard
 - Cases that REQUIRE palpation to make a diagnosis
 - Cases that use a patient history to solidify physical findings
 - Cases that can be controlled by milestone 3
- How do we determine the difficulty of these cases?
 - Getting feedback on the cases

A Case for Your Consideration

- **HISTORY:** A 27 year old female presents for an evaluation of abdominal pain. She describes the pain as gradual in onset, moderate to severe, constant, progressive worsening over time, and ongoing for approximately 6 hours prior to presentation. The location is described as peri-umbilical. She describes the following associated findings: nausea and vomiting, anorexia, and feeling feverish. The patient's past medical history is unremarkable.
- **PHYSICAL EXAMINATION:** General Appearance is grossly unremarkable. **VITAL SIGNS** are remarkable for the following: temperature 37.5 °C. **THORAX** and **LUNGS** are unremarkable. **ABDOMINAL EXAM/INSPECTION** is unremarkable. **ABDOMINAL AUSCULTATION** reveals: decreased bowel sounds.

The Palpatory Findings

- ABDOMINAL PALPATION reveals: tenderness in the right lower quadrant, no abdominal guarding, and pushback in the right lower quadrant.
- Diagnosis?
- How difficult was this case?

Another Case for Your Consideration

- **HISTORY:** A 67 year old female presents for an evaluation of abdominal pain. She describes the pain as gradual in onset, mild in nature, constant, progressive worsening over time, and ongoing for less than 5 hours prior to presentation. The location is described as non-specific, and worsening with defecation. She describes the following associated findings: anorexia, and feeling feverish. The patient's past medical history is positive for the following: alcohol abuse.
- **PHYSICAL EXAMINATION:** General Appearance is grossly unremarkable. **VITAL SIGNS** are remarkable for the following: temperature 37.2 °C. **THORAX** and **LUNGS** are unremarkable. **ABDOMINAL EXAM/INSPECTION** is unremarkable. **ABDOMINAL AUSCULTATION** reveals: decreased bowel sounds.

Yet More Palpatory Findings

- ABDOMINAL PALPATION reveals: tenderness in the left lower quadrant, and no abdominal guarding.
- Diagnosis?
- How difficult was this case?

The Answer Booklet

Before palpating the abdomen	After palpating the abdomen
<p> <input type="checkbox"/> A. Upper GI Etiology <input type="checkbox"/> B. Cholecystitis <input type="checkbox"/> C. Pancreatitis <input type="checkbox"/> D. Choledocolithiasis <input type="checkbox"/> E. Mesenteric Infarction <input type="checkbox"/> F. Small Bowel Obstruction <input type="checkbox"/> G. Acute Enteritis <input type="checkbox"/> H. Appendicitis <input type="checkbox"/> I. Diverticulitis <input type="checkbox"/> J. Ovarian Cyst <input type="checkbox"/> K. Ovarian Torsion <input type="checkbox"/> L. Constipation <input type="checkbox"/> M. Urinary Tract Infection </p>	<p> <input type="checkbox"/> A. Upper GI Etiology <input type="checkbox"/> B. Cholecystitis <input type="checkbox"/> C. Pancreatitis <input type="checkbox"/> D. Choledocolithiasis <input type="checkbox"/> E. Mesenteric Infarction <input type="checkbox"/> F. Small Bowel Obstruction <input type="checkbox"/> G. Acute Enteritis <input type="checkbox"/> H. Appendicitis <input type="checkbox"/> I. Diverticulitis <input type="checkbox"/> J. Ovarian Cyst <input type="checkbox"/> K. Ovarian Torsion <input type="checkbox"/> L. Constipation <input type="checkbox"/> M. Urinary Tract Infection </p>
<p>Please rate your confidence in your above answers:</p> <p> Not at all confident Extremely confident 1 2 3 4 5 </p>	<p>Please rate your confidence in your above answers:</p> <p> Not at all confident Extremely confident 1 2 3 4 5 </p>

Selection of Abnormalities for Detection

- Abdominal Abnormalities:
 - 1. Appendix tenderness + Guarding
 - 2. Left Lower colon
 - 3. Gallbladder + Guarding
 - 4. Gastric/Pancreatic
 - 5. L/R Ovary
 - 6. Urinary Bladder Tenderness/Enlargement
 - 7. Hepatomegaly
 - 8. Splenomegaly

Selection of Abnormalities for Detection

- Rationale:
 - Tenderness vs. organomegaly
 - The unique case of the urinary bladder
 - Determining a proper distribution
 - Pairing based on difficulty AND location
 - Proposed pairings:
 - A: Appendix/Gastric
 - B: Urinary Bladder/Hepatomegaly
 - C: Left Ovary/Splenomegaly
 - D: Gallbladder/Left Lower Colon

The Answer Booklet Returns

- A. Hepatomegaly
- B. Splenomegaly
- C. Gastric Tenderness
- D. Gallbladder Tenderness
- E. Pancreatic Tenderness
- F. Appendix Tenderness
- G. Left Ovary Tenderness
- H. Right Ovary Tenderness
- I. Urinary Bladder Tenderness
- J. Enlarged Urinary Bladder with Tenderness
- K. Left Lower Colon Tenderness

Is guarding present?

No Maybe Yes

Is rebound tenderness present?

No Maybe Yes

Please rate your confidence in your above answers:

Not at all confident 1 2 3 4 5 Extremely confident

Conclusion

- Next Steps:
 - Finalize the cases
 - Complete the initial assessment of the first year PA class
 - Before early September
 - Complete the assessment with the second year PA class
 - Complete the follow-up assessment with the first year PA class following their lecture/clinical exposure to the abdomen (roughly September 8)

Questions?

- Your questions will be answered in the order received.
 - We are currently receiving a large volume of questions; we appreciate your patience and will attempt to assist you as soon as possible.